

## Case Report

### COVID-19: A NEW THREAT TO THE NERVOUS SYSTEM IN CHILDREN

Monir Hossain 1, Manifa Afrin 1, Mahfuza Shirin 1, Abdur Razzaque 1, Shiplu Kumar Das 1, Sultana Razia 1, Nayeema Roshni 1

#### Author's Affiliation:

1- Department of Pediatrics, Universal Medical College Hospital, Dhaka, Bangladesh

#### Correspondence:

Manifa Afrin, Phone: +8801712089368, Email: manifaafrin@gmail.com

Received on: 03-Oct-2020

Accepted for Publication: 27-Dec-2020

#### ABSTRACT

Systemic COVID-19 (SARS-CoV-2) is a pandemic disease all over the world. Peripheral nervous system related complications have not been yet reported in COVID-19 infected children. As a presentation or complication as GBS have not been described in SARS-CoV-2 infected pediatrics patients. Here, we report a 3 years old covid-19 positive boy who was suffering from GBS like initial presentation followed by unconsciousness.

**Keywords:** covid-19, GBS

#### INTRODUCTION

COVID-19, the novel corona virus disease was first discovered in Wuhan, China in December 8, 2019 as severe acute respiratory syndrome by corona virus type 2(SARS-CoV-2).<sup>1</sup> According to various data, children are less likely develop multi-organ failure or become seriously ill than older peoples.<sup>2</sup> The World Health Organization declared COVID-19 a Public Health Emergency on 30 January, 2020<sup>1</sup> as well as worldwide pandemic infection on 11 March.<sup>3</sup> Cough, fever, fatigability and shortness of breath are the common symptoms of Covid-19 but most of the affected people have no or mild symptoms.<sup>1</sup> Among 214 covid-19 hospitalized patient in Wuhan, 36.4% had neurological symptoms like headache, dizziness, hypogeusia & neuralgia with other complications as impaired consciousness, encephalopathy, paresthesia or acute cerebrovascular disease.<sup>4,5</sup> More recently, adult individuals present with polyneuritis<sup>6</sup>, Miller-Fisher syndrome and steroid responsive encephalitis<sup>7</sup> which are an immune-mediated neurological syndrome.<sup>2</sup> Here, we report a 3 years old covid-19 positive boy who was presented with peripheral neurological symptoms like GBS. Instead of available data, pediatricians, neurologists and other clinicians should be aware of such type of SARS-CoV-2 associated neurologic findings.

#### CASE PRESENTATIONS

3 years old boy Arabi, was admitted with the complaints of weakness of lower limbs for last 3 days followed by unable to stand and walk since morning. He had history of fever for one day 7 days back. The boy was suffered from GBS 20 months back and cured at that time without any consequences. The patient was admitted for further workup. After admission, he was conscious and reflexes & muscle power was diminished only in lower limbs but upper limbs are normal and diagnosed as recurrent GBS. The child was deteriorating, gradually upper limbs were involved, diminished respiratory efforts and increase O<sub>2</sub> demand. For these conditions, the boy was ventilated but condition is not improved. Next day he lost his consciousness and all muscles were flaccid & muscle power became 0/5. GCS gradually fall and no self-respiration on 4<sup>th</sup> day of ICU admission. No nuchal rigidity was noted. Due to encephalopathic condition of the patient, neurology was consulted and treated empirically with ceftriaxone, dexamethasone, acyclovir and IVIG. CSF study did not reveal any evidence of CNS infection, no abnormality in MRI of brain & spinal cord but due to progression of symptomology he was tested nasopharyngeal swab for covid-19 and found positive. Chest x-ray had pneumonic infiltration in left upper & mid zone and D-dimer (10000ng/L, normal <500ng/ml), LDH (1261U/L, normal 125-220), S ferritin(25ng/ml, normal 25-350) was raised. Based on other center experiences, the baby was treated with flavipiravir, enoxaparin and continues antibiotics & antiviral therapy. This boy was critically ill and on

mechanical ventilation with poor prognosis but responsive to noxious stimuli after starting specific antiviral & antithrombotic therapy.

## DISCUSSION

SARS-CoV-2 infected patients have variable presentations or symptoms, fever or a mild cough to pneumonia, even extensive multisystem inflammatory syndrome in children which later affects organs and blood vessels. Recently some clinical data have disclosed that some of the patients with COVID-19 have neurological manifestations.<sup>8</sup> More recently, some adults presented with Miller-Fisher syndrome, polyneuritis<sup>6</sup> or steroid responsive encephalitis without usual symptoms.<sup>7</sup> Neurology department of Great Ormond Street Hospital for Children reported four SARS-CoV-2 infected children were presented with new onset neurological symptoms. Only eight adults have been reported as covid-19 associated GBS as presenting complaints without respiratory problems from China, Iran and Italy but no data in pediatric age group.<sup>9</sup> In northern Italy, Toscano reported five patients of GBS after onset of covid-19, during that period 1000 to 1200 patients were admitted with covid-19.

Corona virus is primarily respiratory virus but as a neurotropic virus it can affect brain, spinal cord as well as peripheral nerves. The target receptor attached angiotensin converting enzyme-2 receptor of the cells and after subsequent internalization into the cell the SARS-CoV-2 RNA released in cytoplasm. Then translation-replication occurred, after formation of envelope proteins RNA incorporated into virus and released in the circulation.<sup>10</sup> These ACE 2 receptors are found in glial cells of brain & spinal neurons and SARS-CoV-2 can attach, multiply and damage these nervous tissues.<sup>2,9</sup> A cohort study shows neurological symptoms are as a part of systemic auto inflammatory disease associated with raised systemic inflammatory markers. We also found similarity in this reported case. The peripheral nervous system involvement as presenting symptom are rare in pediatrics population, but it can be seen in this age group.<sup>2</sup> More recently, another study reported isolated CNS manifestations in covid-19 patients.<sup>11</sup>

CSF study	
<b>Colour</b>	Crystal clear
<b>Appearance</b>	Clear
<b>Reaction</b>	Alkaline
<b>Clot formation</b>	Absent
<b>Total WBC count</b>	02/cmm
<b>Cell morphology</b>	Neutrophils-00, lymphocytes-100%
<b>Gram stain</b>	Not found
<b>AFB stain</b>	Not found
<b>Sugar</b>	8mmol/L (2.2-4.2 normal value)
<b>Protein</b>	51mg/dl (15-45 normal value)

Table 1: CSF study

According to Toscano, five adult patients showed 5 to 10 days interval between the onset of Covid-19 symptoms and the first symptoms appeared as Guillain–Barré syndrome.<sup>12</sup> Our patient also presented on 4<sup>th</sup> day of infection and develop flaccid tetraplegia within 72 hours. Toscano also stated that, two patients had a normal protein level and other patients had less than 5/cumm white cell count on cerebrospinal fluid (CSF) analysis.<sup>12</sup> These findings are similar in our baby. In MRI after gadolinium administration, Toscano showed caudal nerve roots enhancement in two patients, facial nerve enhancement in one patient, and no nerve signal changes in two patients.<sup>12</sup> We did MRI without contrast and no abnormality was seen. Among 20 case reports, 90 patients with COVID-19 associated neurologic signs, 37 patients (41%) with laboratory-confirmed COVID-19 infection had no acute abnormalities on brain radiology (CT or MRI).<sup>13</sup>

Toscano et al again reported that among all GBS patients who received intravenous immunoglobulin (IVIg) and one plasma exchange, only two cases were improved including “mild improvement”. We found similarity in our patient who received adequate dose of IVIG but less responsive.

Through this report we want to highlight a new presenting sign of COVID-19 patients as peripheral neuropathy including GBS. COVID-19 positive patients can present with peripheral neuropathy in hospital emergency with or without common clinical features like cough, fever or they may develop during their hospital stay.

Due to paucity of details and rare presentation of post infectious immune mediated disease following COVID-19 with GBS and its variants, is unclear to describe the relationship between COVID-19 and GBS. Further large-scale studies are required to prove this statement.

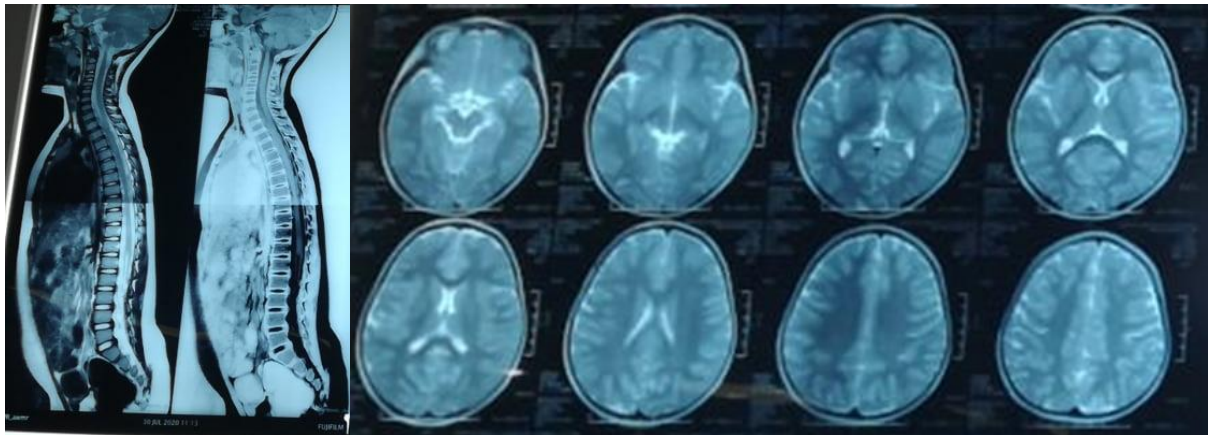


Figure 1: MRI - MRI reveals no abnormality in brain and spinal cord

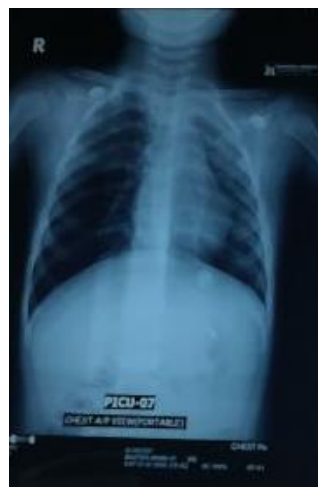

Figure 2: Chest Xray - Chest X-ray shows pulmonary infiltration in left lung

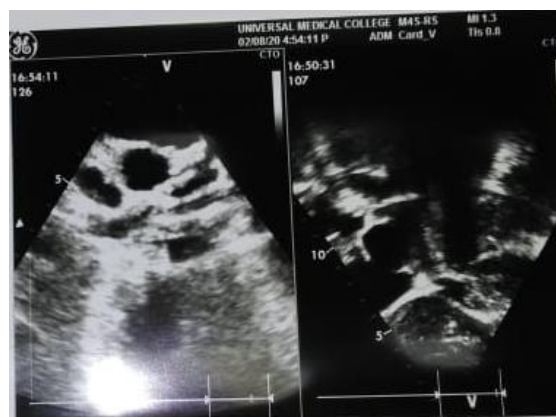

Figure 3: Echo - Echocardiogram shows normal structure and good ventricular function of heart

## CONCLUSION

Now physicians as well as pediatricians must be aware of covid-19 children can be presented with GBS in acute condition or during hospitalization.

## REFERENCES

1. Koralnik IJ and Tyler KL. COVID-19: A Global Threat to the Nervous System. *ANN NEUROL* 2020; 88:1–11.
2. Mannan OA, Eyre M, Löbel U, Bamford A, Eltze C, Hameed B, Hemingway C, Hacoheh Y. Neurologic and Radiographic Findings Associated With COVID-19 Infection in Children. *JAMA Neurology*. y Published online July 1,2020. doi:10.1001/jamaneurol.2020.2687
3. WHO Director-General's opening remarks at the media briefing on COVID-19 – 11 March 2020. 11 March 2020. Available at <https://www.who.int/dg/speeches/detail/who-director-general-s-opening-remarks-at-the-mediabriefing-on-covid-19—11-march-2020> (accessed 22nd April 2020).
4. Mao L, Jin H, Wang M, Hu Y, Chen S, He Q, Chang J, Hong C, Zhou Y, Wang D, Miao X, Li Y, Hu B. Neurologic manifestations of hospitalized patients with coronavirus disease 2019 in Wuhan, China. *JAMA Neurol* 2020. <https://doi.org/10.1001/jamaneurol.2020.1127>
5. Helms J, Kremer S, Merdji H, Clere-Jehl R, Schenck M, Kummerlen C, et al. Neurologic Features in Severe SARS-CoV-2 Infection. *N Engl J Med* 2020. <https://doi.org/10.1056/NEJMc2008597>.
6. Gutiérrez-Ortiz C, Méndez A, Rodrigo-Rey S, et al. Miller Fisher syndrome and polyneuritis cranialis in COVID-19. *Neurology*. 2020; 10.1212/WNL.0000000000009619. doi:10.1212/WNL.0000000000009619
7. Pilotto A, Odolini S, Stefano Masciocchi S, et al Steroid-responsive encephalitis in COVID-19 disease. *Ann Neurol*. Published online May 17, 2020. doi:10.1002/ana.25783.
8. Wu Y, et al. Nervous system involvement after infection with COVID-19 and other coronaviruses. *Brain, Behavior, and Immunity*. 2020;( 87):18–22.
9. Ahmad I, Rathore FA. Neurological manifestations and complications of COVID-19: A literature review. *Journal of Clinical Neuroscience*. 2020;(77):8–12. <https://doi.org/10.1016/j.jocn.2020.05.017>
10. Baig AM, Khaleeq A, Ali U, Syeda H. Evidence of the COVID-19 virus targeting the CNS: tissue distribution, host virus interaction, and proposed neurotropic mechanisms. *ACS Chem Neurosci* 2020 Apr 1; 11(7):995–8.
11. Gofshhteyn JS, Shaw PA, Teachey DT, et al. Neurotoxicity after CTL019 in a pediatric and young adult cohort. *Ann Neurol*. 2018;84(4):537-546. doi:10.1002/ana.25315
12. Toscano G, Palmerini F, Ravaglia S, et al. Guillain-Barre syndrome associated with SARS-CoV-2. *N Engl J Med* 2020. <https://doi.org/10.1056/NEJMc2009191>.
13. Katal S, et al. Neuroimaging and neurologic findings in COVID-19 and other coronavirus infections: A systematic review in 116 patients, *J Neuroradiol*.2020; <https://doi.org/10.1016/j.neurad.2020.06.007>.